

Cervical Arthroplasty in the Management of Spondylotic Myelopathy

Lali H. S. Sekhon

Department of Neurosurgery and Spinal Injuries Unit, Royal North Shore Hospital, and University of Sydney, Sydney, New South Wales, Australia

Summary: Cervical spinal cord compression managed via an anterior approach with an arthrodesis is associated with a decreased range of motion and accelerated adjacent segment degeneration. Artificial cervical disc replacement may address these problems. A series of seven cases (three women, two men; age 31–55 years) of anterior cervical decompression and placement of an artificial disc prosthesis is presented. A total of nine Bryan cervical disc prostheses (Spinal Dynamics Corp., Mercer Island, WA) were placed. Clinical and radiologic follow-up was performed at 24 hours, 6 weeks, 3 months, 6 months, and then yearly (mean follow-up period 6.29 months, range 1–17 months). There were no complications. There was an improvement in Nurick grade by 0.72 grade ($P < 0.05$) and Oswestry Neck Disability Index score by 51.4 points ($P < 0.0001$). Motion was preserved. Improvement in lordosis occurred in 29% of cases. The spinal cord was decompressed on postoperative imaging. Cervical arthroplasty after anterior cervical decompression at one or more levels represents an exciting tool in the management of spinal cord compression secondary to spondylotic disease or acute disc prolapse. This is the first study that looks specifically at cervical arthroplasty for cervical myelopathy. Longer follow-up will reveal any delayed problems with artificial disc implantation, but in the short term, this technique offers an excellent outcome. **Key Words:** arthroplasty, Bryan disc, cervical myelopathy, fusion, stenosis

INTRODUCTION

Cervical myelopathy and cord compression due to spondylotic disease (cervical spondylotic myelopathy [CSM]) or acute disc herniation is a common spinal disorder, with controversy over the role and timing of surgical intervention as well as the optimal treatment.^{1–8} Over the last 50 years, various combinations of anterior and posterior instrumented surgeries have been devised and refined and continue to be used. In the absence of arthrodesis, kyphotic deformity is always a feared complication.^{9,10} The problem with interbody or posterior cervical fusion is that typically a reduction in effective motion occurs and there are significant morbidities associated

with bone graft harvest.¹¹ Coupled with this, the incidence of adjacent segment deterioration, requiring reoperation, has been quoted as being as high as 3% per year.¹² Consequently, there has been a more recent emphasis on surgical techniques such as cervical laminoplasty or cervical disc arthroplasty to maintain motion, avoid deformity, reduce adjacent segment stresses, and allow for an adequate decompression without having to use bone graft.

This study reports the use of artificial disc implantation in the management of spinal cord compression and cervical myelopathy. Although the use of the Bryan disc (Spinal Dynamics Corp., Mercer Island, WA) in cervical spine disease has been reported before,^{13,14} this is the first series specifically evaluating the use of cervical arthroplasty in spinal cord compression due to spondylotic disease or acute disc herniation.

PATIENTS AND METHODS

Seven patients were presented in this study, recruited over a 16-month period from July 2001 until November

Received January 15, 2003; accepted April 10, 2003.

Address correspondence and reprint requests to Dr. Lali H. S. Sekhon, 799 Pacific Highway, Level 10, Tower B, Chatswood, NSW, 2067, Australia. E-mail: lali@spinalneurosurgery.com

2002, with all surgeries performed by a single surgeon. All patients had preoperative magnetic resonance imaging (MRI) scans of the cervical spine demonstrating spinal cord compression and/or had a clinical cervical myelopathy. All would normally have qualified for and be offered an anterior cervical decompression and fusion with iliac crest autograft and instrumentation. Exclusion criteria for this group included kyphotic deformity, severe multilevel spondylotic disc degeneration, spinal cord injury with possible instability, and pure radiculopathy secondary to posterolateral disc protrusion or foraminal stenosis. If the affected disc space could not be visualized on a lateral supine cervical x-ray, cervical arthroplasty was not offered. The group was not randomized but prospectively followed. All patients requested cervical arthroplasty when the various surgical options were discussed.

The demographics of the patients selected for this study are summarized in Table 1. There were four men and three women with ages ranging from 31 to 55 years (mean age 42.9 years), and symptoms were present from 0.75 to 72 months (mean 16 months). Two of seven patients (29%) were active cigarette smokers. All patients had a detailed neurologic examination and Nurick grading¹⁵ preoperatively. All patients completed an Oswestry Neck Disability Index assessment (ONDI)¹⁶ and also scored their neck and arm symptoms from 0 to 3 (0 = nil, 1 = mild, 2 = moderate, 3 = severe). All patients had preoperative static and dynamic cervical spine x-rays, MR scanning, and computed tomography (CT) scanning of the cervical spine. All imaging studies were independently reviewed. It was explained that if intraoperatively arthroplasty could not be done, an interbody fusion would be performed.

Preoperative assessment revealed three of seven patients (43%) had myelopathic dysfunction of at least Nurick grade II. Five of seven patients (71%) had symptoms or signs of radiculopathy in addition to myelopathic symptoms or signs. No patient had pure radiculopathy. Four of seven patients (57%) had high signal in the spinal cord, suggesting edema or myelomalacia on T2-weighted MRI. Typical preoperative imaging is shown in Figure 1. Osteophytic compression was present in six of seven cases (86%), with two of seven cases (29%) having significant

disc herniation. No patient had preoperative kyphotic deformity, but six of seven did have loss of normal cervical lordosis (86%). Dynamic cervical x-rays preoperatively showed no evidence of instability or hypermobility.

Surgical intervention followed the recommendations by the designers of the Bryan cervical disc prosthesis (Spinal Dynamics Corp.). The operative technique has been described elsewhere.^{13,14} In brief, after the administration of general anesthesia, endotracheal intubation was effected and the procedure performed in the supine position under fluoroscopic control. The head was placed on a soft cushion in gentle extension with a rolled towel behind the neck. For single-level disease, a left-sided transverse cervical skin incision was used, and for two-level disease, either this incision or an oblique left-sided paramedian incision was used. On two occasions, the C6–C7 disc space was difficult to visualize radiographically in the supine position, although it had been well visualized in the erect position and careful arm retraction as well as digital fluoroscopy coned down to the affected level was required. No case was abandoned because of this problem. An extensile exposure of the anterior cervical spine was effected, and after standard microsurgical decompression of the spinal cord, one or more artificial disc prostheses were placed. The posterior longitudinal ligament was excised in every case. The sizes of the prosthesis ranged in diameter from 14 to 17 mm (see Table 3). No collar was placed postoperatively. All patients were monitored in our high-dependency unit overnight and mobilized the day following surgery. All patients were discharged within 48–72 hours after surgery. All patients returned to work within 2–4 weeks after surgery.

Postoperative evaluations incorporated the same interval clinical and radiologic evaluations that were performed preoperatively. Postoperative evaluation was performed at 24 hours, 6 weeks, 3 months, 6 months, and then yearly. An independent radiologist assessed all imaging. Static and dynamic x-rays were performed at every follow-up point, but MR scanning was done only at 6 weeks and 12 months. CT scanning was performed at 24 hours and then 6 and 12 monthly. Follow-up periods ranged from 1 to 17 months (mean 6.3 months). An assessment of

TABLE 1. Patient demographics

Patient no.	Age (yrs)	Sex	Preop. Nurick grade	Preop. neck symptoms ^a	Preop. arm symptoms	Preop. ONDI	Smoker	Acute disc herniation	Cervical spondylosis	Duration of symptoms (mos)	Cord compression on MR scanning	Cord signal change of MR	Preop. cervical deformity
1	38	M	II	1	0	42	No	No	Yes	3	Y	Y	Loss of lordosis
2	55	F	I	2	3	76	No	No	Yes	6	Y	N	Loss of lordosis
3	46	M	I	1	3	66	Yes	Yes	Yes	0.75	Y	N	Loss of lordosis
4	47	M	III	1	1	34	No	No	Yes	4	Y	Y	Loss of lordosis
5	49	F	I	2	3	58	No	No	Yes	9	Y	Y	Loss of lordosis
6	31	M	I	3	1	80	No	No	Yes	72	Y	N	Nil
7	34	F	III	2	3	42	Yes	Yes	Yes	18	Y	Y	Loss of lordosis

^a0 = nil symptoms; 1 = mild symptoms; 2 = moderate symptoms; 3 = severe symptoms.

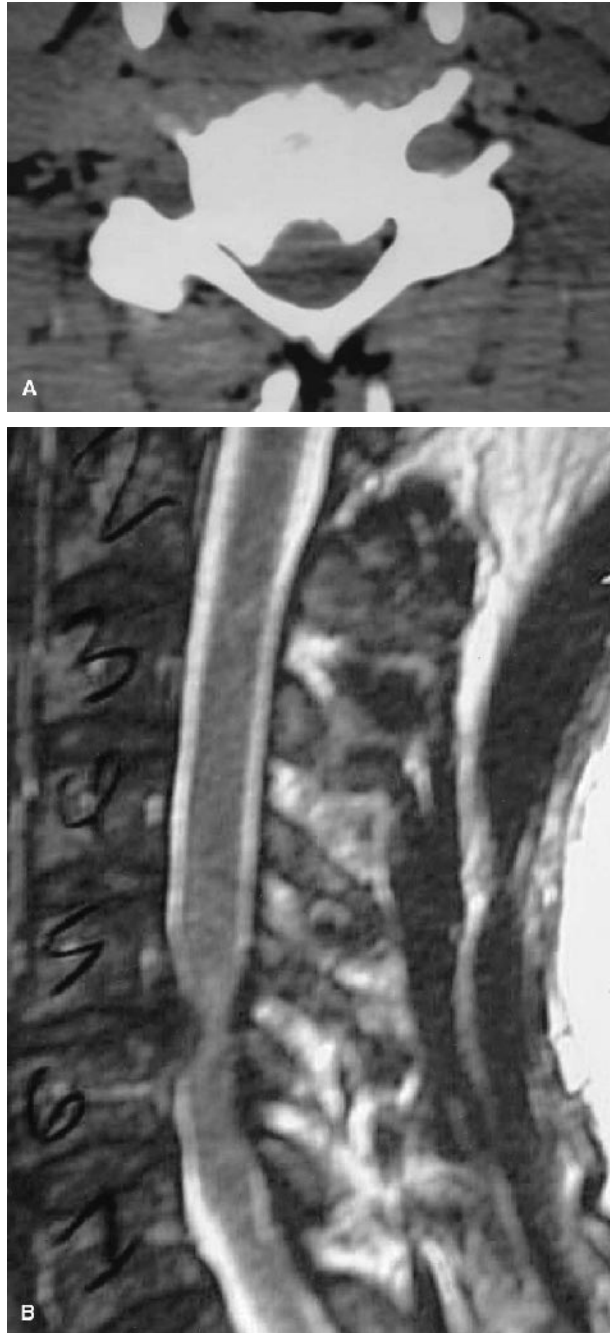


FIGURE 1. Preoperative axial CT scan (A) and sagittal MR scan (B), both showing spinal cord compression secondary to spondylotic disease. There is high signal in the spinal cord on the MR scan, and compression is primarily secondary to spondylotic osteophytes, best visualized on the CT.

overall surgical outcome was made using Odom's criteria¹⁷ (Table 2) in addition to the other outcome measures discussed previously. The surgical and postoperative outcomes are summarized in Table 3. The pre- and postoperative Nurick grades, ONDI scores, and arm and neck symptom scores were compared using two-sample *t* tests

TABLE 2. Odom's criteria¹⁷

Grade	Definition
Excellent	All preoperative symptoms relieved, able to carry out daily occupations without impairment
Good	Minimum persistence of preoperative symptoms, able to carry out daily occupations without significant interference
Fair	Relief of some preoperative symptoms, but whose physical activities were significantly limited
Poor	Symptoms and signs unchanged or worse

paired for means. A *P* value of <0.05 was regarded as significant. All scores were expressed as means \pm SEM.

RESULTS

A total of nine prostheses were inserted in seven patients. In this group, 88% of patients had either the C5–C6 or the C6–C7 level instrumented. There were no complications in the intraoperative or postoperative period, and all patients noted immediate improvement in preoperative symptoms. There were no deaths. No patients were lost to follow-up, and two patients were seen 1 month after surgery as the latest review. All patients had returned to work by 2–4 weeks postoperatively. The postoperative outcome scores listed in Table 3 are the most recent.

Looking first at clinical outcome, it is apparent from Table 3 that there was a significant improvement in subjective neck and arm symptoms. Neck symptom scores improved from 1.71 ± 0.29 to 0.43 ± 0.30 ($P < 0.01$). Arm symptom scores improved from 2.00 ± 0.49 to 0.29 ± 0.29 ($P < 0.01$). The ONDI improved from 56.9 ± 6.8 to 5.40 ± 2.30 ($P < 0.0001$). Both smokers had excellent outcomes. On clinical assessment, there was a statistically significant improvement in the Nurick grade from 1.71 ± 0.36 to 1.00 ± 0.00 ($P < 0.05$). No patient had persisting weakness. Patient 2 did complain of intermittent left arm pain in the C6 distribution but felt it had improved from preoperatively and on imaging there was no residual neural compression. At last follow-up, this patient had persistence of preoperative neck and shoulder discomfort of a lesser degree postoperatively but was able to return to her previous occupation.

Radiologic imaging performed postoperatively is represented in Figures 2–4 and in Table 3. A typical set of postoperative static and dynamic series of x-rays are shown in Figures 2 and 3. Significantly, loss of lordosis was a common preoperative deformity, present in 86% of cases, but some degree of correction did occur in two of seven patients with restoration of cervical lordosis on postoperative imaging. All patients demonstrated a good range of cervical motion on fluoroscopic screening at the final postoperative assessment. It is notable that the in-

TABLE 3. Patient results

Patient no.	Levels replaced	Size of prosthesis (mm)	Follow-up (mos)	Postop. Nurick grade ^b	Postop. Neck symptoms ^{a,c}	Postop. arm symptoms ^{a,d}	Postop. deformity	Postop. ONDI ^e	Outcome according to Odom's criteria
1	C5-C6	15	17	I	0	0	Lossoflordosis	2	Excellent
2	C5-C6	14	14	I	2	2	Lossoflordosis	8	Good
3	C6-C7	15	6	I	0	0	Lossoflordosis	16	Excellent
4	C6-C7	17	3	I	0	0	Lossoflordosis	0	Excellent
5	C5-C6, C6-C7	16 × 2	2	I	0	0	Nil	2	Excellent
6	C6-C7	15	1	I	1	0	Nil	10	Good
7	C4-C5, C5-C6	15, 16	1	I	0	0	Nil	0	Excellent

^a0 = nil symptoms; 1 = mild symptoms; 2 = moderate symptoms; 3 = severe symptoms.

^bWhen compared with preoperative values, statistically significant difference, $P < 0.05$.

^cWhen compared with preoperative values, statistically significant difference, $P < 0.01$.

^dWhen compared with preoperative values, statistically significant difference, $P < 0.01$.

^eWhen compared with preoperative values, statistically significant difference, $P < 0.0001$.

crease in the height of the disc space was less than that attained by placing an anterior interbody strut graft.

CT scanning was often more reliable in assessment of placement of the artificial disc prosthesis postoperatively, particularly with reconstructed views, and clearly showed the adequacy of decompression, as demonstrated in Fig-

ures 3 and 4. The titanium shells did produce artifact on MRI, making the adjacent spinal canal difficult to assess. This occurred in only two of seven patients, but subsequent CT scanning was able to confirm adequate decompression. High signal change in the spinal cord demonstrated on preoperative MR scanning was persistent

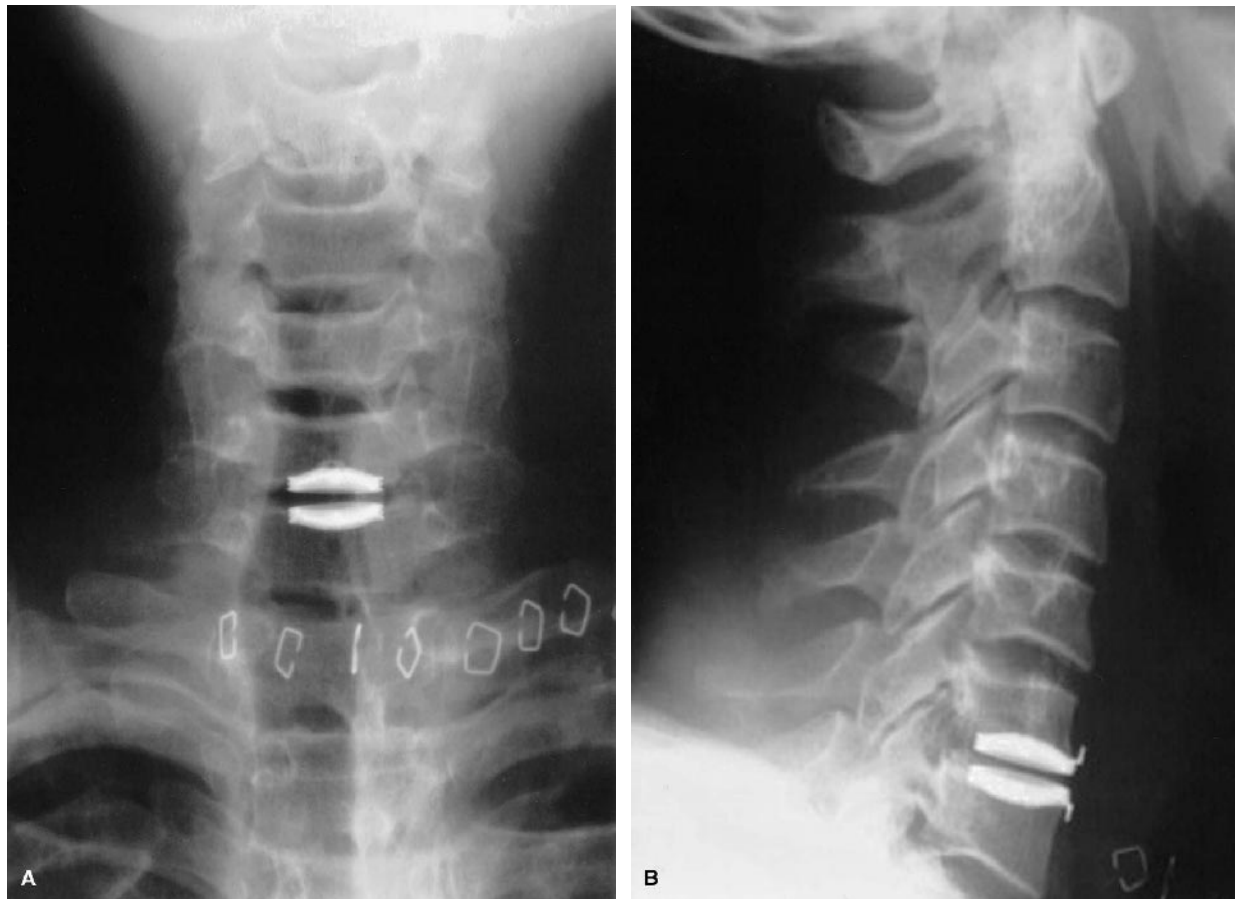

FIGURE 2. Postoperative anteroposterior (A) and lateral (B) x-rays after placement of an artificial disc prosthesis at the C6-C7 level in case 3. The prosthesis is centered on the disc space. Minimal change in disc height occurs compared with preoperative films.

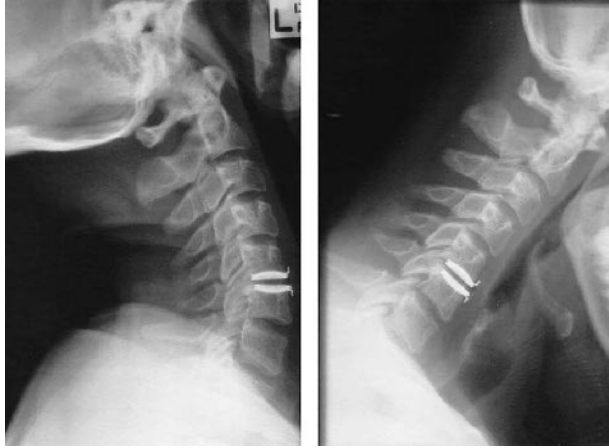

FIGURE 3. Lateral flexion/extension x-rays after placement of a C5–C6 artificial disc prosthesis from case 2. Note that normal movement occurs at the instrumented level, as demonstrated by the crowding, then splaying of the C5 and C6 spinous process.

postoperatively, despite adequate decompression, suggesting this was due to myelomalacia or gliosis rather than edema.

Surgical outcome when measured using Odom's criteria¹⁷ suggested 100% of patients had a good or excellent outcome (see Table 3).

DISCUSSION

This study presents seven patients with clinical or radiologic spinal cord compression who underwent spinal cord decompression and cervical arthroplasty. Although follow-up periods were relatively short, at most recent follow-up, all had good or excellent outcomes with radiologic evidence of spinal cord decompression and improvement in clinical myelopathy. Motion was preserved. Interestingly, there was also commonly an improvement in associated neck pain, which would suggest predominantly nonmechanical causes of pain. Although the numbers are small, smoking did not adversely affect outcome. This is an important finding that needs further exploration because of the impact of smoking on spinal arthrodesis. Finally, some minor correction of deformity did occur in two patients with restoration of a normal lordosis. No attempt was made to perform arthroplasty in patients with cervical kyphosis for fear of premature failure of the prosthesis due to excessive loading, but minor deformity did not appear to impact adversely on the outcome.

CSM is the most common acquired cause of spinal cord dysfunction. Described first by Stookey in 1928,¹⁸ it was initially attributed to cord compression by cartilaginous nodules of degenerated disc material. The definition of CSM, as a distinct clinical entity, was refined by Clark and Robinson in 1956, when they distinguished this degenera-

tive condition from myelopathy caused by acute disc prolapse.¹⁹ CSM is characterized by a progressive chronic segmental compression of spinal cord due to spondylotic change and is the leading cause of spinal cord dysfunction.^{20–22} The principal neuropathologic features are cystic cavitation, gliosis, degeneration, wallerian degeneration of posterior columns, and posterolateral tracts and anterior horn cell loss at the site of compression.^{22,23} The pathologic findings and clinical severity of disease show an excellent correlation.²⁴ Although there have been extensive reports on clinical and pathologic aspects of CSM, little is known regarding the biochemical and molecular mechanisms of neuronal and axonal degeneration in CSM.²⁴ There is general agreement that apoptosis, or programmed cell death, could play a significant role in the delayed death of oligodendrocytes.

Anterior cervical decompression and fusion, with or without instrumentation, is a widespread surgical intervention for CSM and cord compression due to acute disc prolapse. Cervical anterior interbody fusion has, however, been widely accepted as leading to a reduction in normal cervical spine motion and increasing the stress at adjacent levels.^{25–27} Hilibrand et al¹² confirmed a rate of 2.9% per year of developing adjacent segment disease after anterior interbody fusion requiring cervical intervention. Traditionally, the outcome from anterior cervical surgery has been more favorable when compared with posterior decompression, when used in the context of cervical myelopathy.^{28,29} The reasons for failure of posterior laminectomy alone are unclear, but the development of kyphotic deformity or microinstability may be contributory. Cervical laminoplasty^{30–33} and lateral mass plating in combination with laminectomy³⁴ may hold more promise for both a better clinical outcome and less adjacent segment disease. Ventral pathology causing spinal cord compression is still generally better dealt with by an anterior approach, especially when confined to one or two levels.

Spinal arthroplasty has a relatively short history. Despite the ease of access in the cervical spine, spinal disc replacement surgery has historically concentrated on the lumbar spine.^{35–37} Fernstrom³⁸ in 1966 introduced an intracorporeal endoprosthesis that consisted of a stainless-steel ball inserted into the center of a lumbar disc after laminectomy. Although Fernstrom focused on lumbar disc prostheses, he also placed these prostheses in the cervical spine. Cummins et al³⁵ more recently have described their experience with the Cummin artificial cervical joint. This prosthesis is basically a stainless-steel ball-and-socket joint. A major shortcoming of this design has been the inability to instrument more than one level.

The Bryan cervical disc prosthesis (Spinal Dynamics Corp.) was first reported as being used for the management of cervical spondylotic disease in 2002 by Goffin et

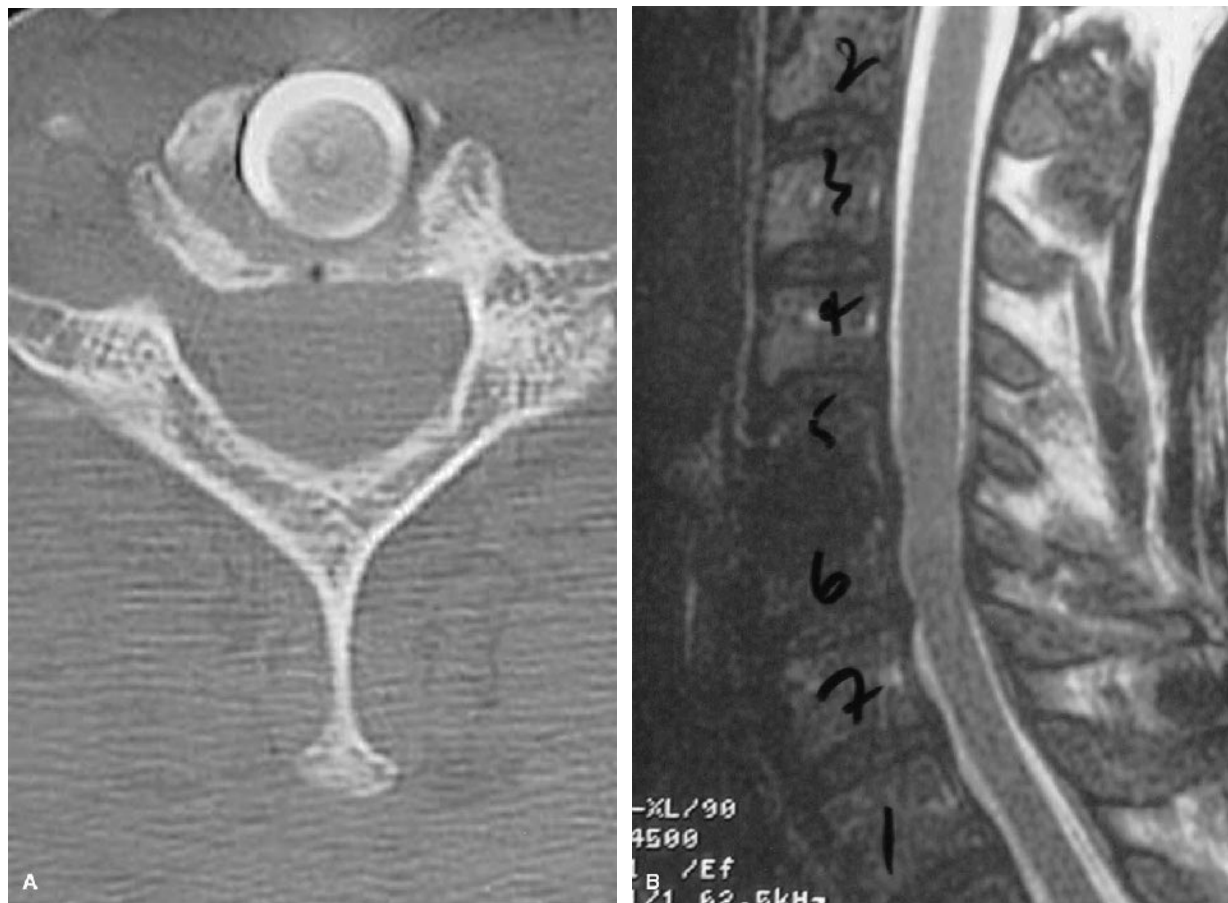


FIGURE 4. Postoperative axial CT scan (A) and sagittal MR scan (B), showing the artificial disc prosthesis after surgery in case 3. On the CT, it is evident that the prosthesis occupies most of the space previously occupied by the intervertebral disc. The MR reveals that the titanium shells do cause artifact with this modality, but the canal is still able to be visualized. This was not the case in every postoperative MR scan.

al¹³ and subsequently by Sekhon.¹⁴ This cervical disc prosthesis consists of a polyurethane nucleus designed to fit between two titanium alloy shells. Each shell has an outer titanium porous coating to encourage bony ingrowth and long-term stability. A polyurethane sheath surrounds the nucleus and is attached to the shells with titanium wire, forming a closed compartment. Sterile saline is placed into the prosthesis, and titanium alloy seal plugs provide for its retention. This prosthesis requires precise milling for its placement, and the technique aims at meticulous centering of the prosthesis. Multiple levels can be instrumented but must be visualized on fluoroscopy. Goffin et al¹³ described the use of cervical arthroplasty in an attempt to maintain cervical motion and avoid arthrodesis after decompression. In their study, 60 patients underwent single-level anterior cervical decompression and placement of an artificial disc prosthesis. Of note is that 93% of the patients of Goffin et al. predominantly had radiculopathy. They reported follow-up at 12 months with clinical success reported at between 85% and 90%. No subsidence of

the devices was noted, and possibly two patients had device migration. No spondylotic bridging occurred at the implanted disc space. Range of motion was preserved, and no device had been explanted or surgically revised.

The pitfalls of anterior cervical decompression and fusion have been discussed, and the risks of adjacent segment disease have fueled the search for alternative interventions. It is hoped that by combining arthroplasty with anterior cervical decompression, the traditionally good outcomes attained by anterior decompressive procedures can be married to the known advantages of maintenance of normal motion.

CONCLUSION

Artificial cervical disc placement combined with anterior cervical decompression promises to usher in a new era in the management of cervical spine disease. Low morbidity combined with an excellent postoperative outcome and avoidance of the known problems associated with

cervical arthrodesis or allograft/autograft usage suggests that this procedure will play an important role in the management of CSM. Smokers appear to fare as well as non-smokers. Multicenter studies are underway, and longer follow-ups are required. The issue of multilevel disc replacement needs contemplation for its potential implications, as does its use in correcting deformity or after previous cervical surgery, but nevertheless this limited series demonstrates that cervical arthroplasty can be successfully used for one- or two-level anterior cord compression in the cervical spine.

REFERENCES

1. Kumar VG, Rea GL, Mervis LJ, et al. Cervical spondylotic myelopathy: functional and radiographic long-term outcome after laminectomy and posterior fusion. *Neurosurgery*. 1999;44:771-777.
2. Adams CB, Logue V. Studies in cervical spondylotic myelopathy. I. Movement of the cervical roots, dura and cord, and their relation to the course of the extrathecal roots. *Brain*. 1971;94:557-568.
3. Adams CB, Logue V. Studies in cervical spondylotic myelopathy. II. The movement and contour of the spine in relation to the neural complications of cervical spondylosis. *Brain*. 1971;94:568-586.
4. Adams CB, Logue V. Studies in cervical spondylotic myelopathy. III. Some functional effects of operations for cervical spondylotic myelopathy. *Brain*. 1971;94:587-594.
5. Carol MP, Ducker TB. Cervical spondylitic myelopathies: surgical treatment. *J Spinal Disord*. 1988;1:59-65.
6. Ebersold MJ, Pare MC, Quast LM. Surgical treatment for cervical spondylitic myelopathy. *J Neurosurg*. 1995;82:745-751.
7. Saunders RL, Bernini PM, Shirreffs TG Jr, et al. Central corpectomy for cervical spondylotic myelopathy: a consecutive series with long-term follow-up evaluation. *J Neurosurg*. 1991;74:163-170.
8. Satomi K, Nishu Y, Kohno T, et al. Long-term follow-up studies of open-door expansive laminoplasty for cervical stenotic myelopathy. *Spine*. 1994;19:507-510.
9. Butler JC, Whitecloud TS. Postlaminectomy kyphosis. Causes and surgical management. *Orthop Clin North Am*. 1992;23:505-511.
10. Orr RD, Zdeblick TA. Cervical spondylotic myelopathy. Approaches to surgical treatment. *Clin Orthop*. 1999;359:58-66.
11. Malloy KM, Hilibrand AS. Autograft versus allograft in degenerative cervical disease. *Clin Orthop*. 2002;394:27-38.
12. Hilibrand AS, Carlson GD, Palumbo MA, et al. Radiculopathy and myelopathy at segments adjacent to the site of a previous anterior cervical arthrodesis. *J Bone Joint Surg (Am)*. 1999;81:519-528.
13. Goffin J, Casey A, Kehr P, et al. Preliminary clinical experience with the Bryan cervical disc prosthesis. *Neurosurgery*. 2002;51:840-847.
14. Sekhon LHS. Two level artificial disc placement for spondylotic cervical myelopathy: case report. *J Clin Neuroscience*. (in press).
15. Nurick S. The natural history and the results of surgical treatment of the spinal cord disorder associated with cervical spondylosis. *Brain*. 1972;95:101-108.
16. Vernon H, Mior S. The Neck Disability Index: a study of reliability and validity. *J Manipulative Physiol Ther*. 1991;14:409-415.
17. Odom GL, Finney W. Cervical disk lesions. *JAMA*. 1958;166:23-28.
18. Stookey B. Compression of the spinal cord due to ventral extradural cervical chondromas. *Arch Neurol Psychiatry*. 1928;20:275-291.
19. Clarke E, Robinson PK. Cervical myelopathy: a complication of cervical spondylosis. *Brain*. 1956;79:510.
20. McCormack BM, Weinstein PR. Cervical spondylosis. An update. *West J Med*. 1996;165:43-51.
21. Bohlman HH, Emery SE. The pathophysiology of cervical spondylosis and myelopathy. *Spine*. 1988;13:843-846.
22. Swagerty DL Jr. Cervical spondylotic myelopathy: a cause of gait disturbance and falls in the elderly. *Kans Med*. 1994;95:226-229.
23. Ohwada T, Ohkouchi T, Yamamoto T, et al. Symptoms and pathological anatomy of the degenerative cervical spine. *Orthopade*. 1996;25:496-504.
24. Fehlings MG, Skaf G. A review of the pathophysiology of cervical spondylotic myelopathy with insights for potential novel mechanisms drawn from traumatic spinal cord injury. *Spine*. 1998;23:2730-2737.
25. Wilms G, Goffin J, Van Driessche J, et al. Posterior fossa venous anomaly and ipsilateral acoustic neuroma: two cases. *Neuroradiology*. 1992;34:337-339.
26. Cherubino P, Benazzo F, Borromeo U, et al. Degenerative arthritis of the adjacent spinal joints following anterior cervical spinal fusion: clinicoradiologic and statistical correlations. *Ital J Orthop Traumatol*. 1990;16:533-543.
27. Matsunaga S, Kabayama S, Yamamoto T, et al. Strain on intervertebral discs after anterior cervical decompression and fusion. *Spine*. 1999;24:670-675.
28. Fessler RG, Steck JC, Giovanini MA. Anterior cervical corpectomy for cervical spondylotic myelopathy. *Neurosurgery*. 1998;43:257-265.
29. Batzdorf U, Flannigan BD. Surgical decompressive procedures for cervical spondylotic myelopathy. A study using magnetic resonance imaging. *Spine*. 1991;16:123-127.
30. Chiba K, Toyama Y. Development of new surgical treatments in spinal surgery: expansive open-door laminoplasty and percutaneous nucleotomy. *Keio J Med*. 2001;50:142-151.
31. Edwards CC, Heller JG, Murakami H. Corpectomy versus laminoplasty for multilevel cervical myelopathy: an independent matched-cohort analysis. *Spine*. 2002;27:1168-1175.
32. Baba H, Chen Q, Uchida K, et al. Laminoplasty with foraminotomy for coexisting cervical myelopathy and unilateral radiculopathy: a preliminary report. *Spine*. 1996;21:196-202.
33. Hase H, Watanabe T, Hirasawa Y, et al. Bilateral open laminoplasty using ceramic laminas for cervical myelopathy. *Spine*. 1991;16:1269-1276.
34. Muffoletto AJ, Hadjipavlou AG, Jensen RE, et al. Techniques and pitfalls of cervical lateral mass plate fixation. *Am J Orthop*. 2000;29:897-903.
35. Cummins BH, Robertson JT, Gill SS. Surgical experience with an implanted artificial cervical joint. *J Neurosurg*. 1998;88:943-948.
36. David T. Lumbar disc prosthesis. *Eur Spine J*. 1993;1:254-259.
37. Enker P, Steffee A, McMillin C, et al. Artificial disc replacement. Preliminary report with 3-year minimum follow up. *Spine*. 1993;18:1061-1070.
38. Fernstrom U. Arthroplasty with intercorporeal endoprosthesis in herniated disc and in painful disc. *Acta Chir Scand (Suppl)*. 1966;355:154-159.